

Accuracy of ultrasound-guided intra-articular injection of cervical facet joints in horses: a cadaveric study

J. V. NIELSEN, L. C. BERG, M. B. THOEFNER[†] and P. D. THOMSEN*

Departments of Anatomy and Physiology and [†]Large Animal Surgery, The Royal Veterinary and Agricultural University of Copenhagen, Bülowsvej 17, DK-1870 Frederiksberg C, Denmark.

Keywords: horse; neck; ultrasonography; articular facet; intra-articular facet joint injection

Summary

Reasons for performing study: Intra-articular facet joint injection is an established diagnostic procedure in human medicine but there are no reports on its reliability in equine practice.

Objectives: To investigate the accuracy of ultrasound-guided intra-articular injections of the cervical facet joints and to estimate factors influencing the accuracy.

Methods: Sixty injections with blue dye were performed on the facet joints between 2nd and 7th cervical vertebra (C2–C7) on horses subjected to euthanasia for nonorthopaedic reasons. The facet joints were subsequently dissected to verify accuracy of deposition.

Results: Seventy-two percent of the injections were found to be intra-articular, 17% were intracapsular and a total of 98% were within 1 mm of the joint capsule. There was a marked effect of gained experience ($P < 0.01$), but not of other factors tested.

Conclusions and potential relevance: The results of the present study do not translate directly to injections performed in live horses, but they indicate that the method can be applied as a diagnostic as well as therapeutic procedure in C2 to C7 and that is advisable to practise injections on cadaver specimens before applying the technique.

Introduction

Nerve blocks and intra-articular injections are well-established procedures in equine medicine, supplementing systematic clinical examination in the precise diagnosis of painful conditions and widely used in the treatment of certain joint diseases (McIlwraith 1998; Moore 1999). Refinement of these techniques in recent years, for example by ultrasound-guided injections, has further increased diagnostic sensitivity and the successful treatment of equine lameness. There are, however, areas that have received little attention, such as the diagnosis and treatment of cervical pain, despite the difficulties in diagnosing these lesions and in assessing some radiographic findings of the cervical facet joints (Ricardi and Dyson 1993). This may be due to difficulties in ensuring that the analgesics used are correctly deposited and, therefore, of diagnostic value. In human medicine, accurate intra-

articular deposition is ensured mainly by palpation or by the use of fluoroscopy with secondary arthrography (Barnsley *et al.* 1994; Kaplan *et al.* 1998; Slipman *et al.* 2001), but ultrasound-guided intra-articular injections in facet joints have also been described (Külmer *et al.* 1997). Palpation-guided intra-articular injections or the use of fluoroscopy have not, to our knowledge, been reported in equine medicine. In a recent study, we showed the normal ultrasonographic appearance of the cervical region and found the equine cervical facet joints to be easy to both locate and clearly visualise using ultrasonography (Berg *et al.* 2003). In addition, the method of ultrasound-guided injections of facet joints in horses has been reported briefly by Grisel *et al.* (1996) and Snyder and Spier (2001). Despite the potential use of this method, we have found no investigations of its reliability. Therefore, the objective of the present study was to investigate the accuracy of ultrasound-guided intra-articular injections of the cervical facet joints and to estimate the factors influencing this accuracy.

Materials and methods

Necks

The study was performed on 8 necks from horses subjected to euthanasia due to nonorthopaedic reasons at the Royal Veterinary and Agricultural University, Copenhagen, Department of Clinical Studies, Large Animal Surgery. The horses weighed mean 500 kg (range 450–600 kg) were of average body condition and had similar muscle proportions on the neck. No clinical examination of the neck region was performed prior to euthanasia. The necks, including the 5 joints from the 2nd (C2) to the 7th (C7) cervical vertebrae, were separated from the rest of the body. It would have been an advantage if the facet joint C7–T1 could have been included, since this is far more difficult to visualise ultrasonographically due to the deeper location beneath part of the pectoral girdle musculature and caudomedial to the craniodorsal margin of the scapula. However, this was not possible as the horses were regular patients from the large animal hospital and therefore had to go through a routine *post mortem* examination, which rendered that part of the carcass severely damaged. For all necks the injections were divided, with one operator performing the injections on one side followed by the other operator injecting the other side. None of the operators had

*Author to whom correspondence should be addressed.

[Paper received for publication 12.08.02; Accepted 20.12.02]

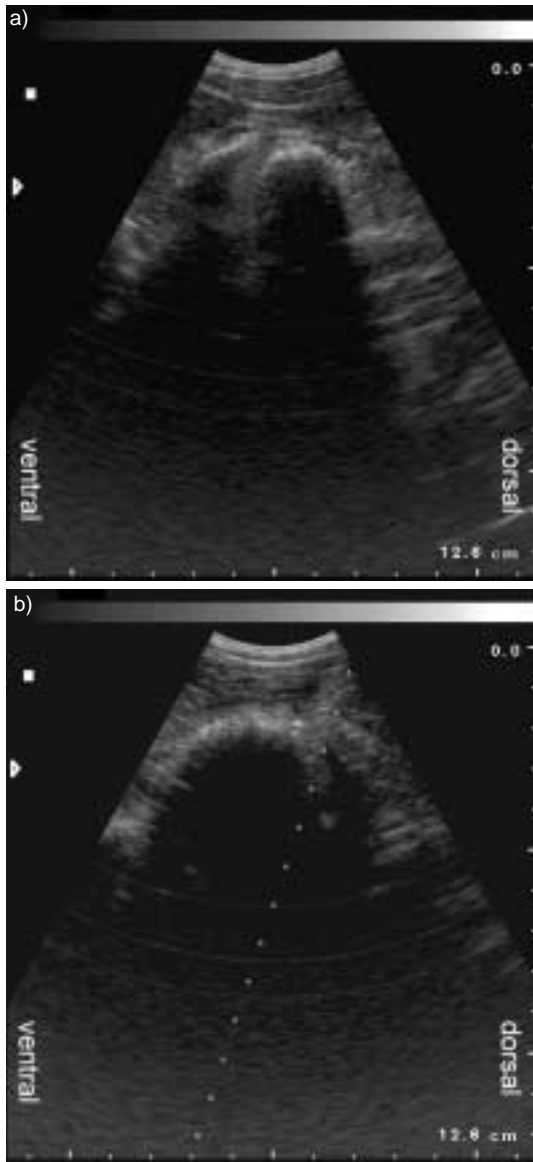


Fig 1: Ultrasound images of articular facet joints. a) An articular facet joint with a clear joint space. b) Another articular facet joint with reflection from the needle in the top right-hand corner and the needle path indicated on the screen.

previous experience with ultrasound-guided procedures or facet joint injections; they alternated between the left and right sides of the neck throughout the study. The injections were performed on 2 necks per week over a period of 6 weeks, with a time lapse of 2 weeks between Necks 3 and 4. The necks were placed on the side lying straight on a table. If large amounts of *post mortem* subcutaneous emphysema were present, it was necessary to remove the skin and subcutis. The impact of this was examined in the statistical analysis.

Equipment and injections

The facet joints were located by ultrasound as described by Berg *et al.* (2003) using the B&K Medical Ultrasound System 3535¹ and a 5 MHz curved linear array transducer with or without needle-guide attachment (Fig 1). A fixed set-up of 40% gain, a resolution of 5 and a frame rate of 60 frames/sec was used with the

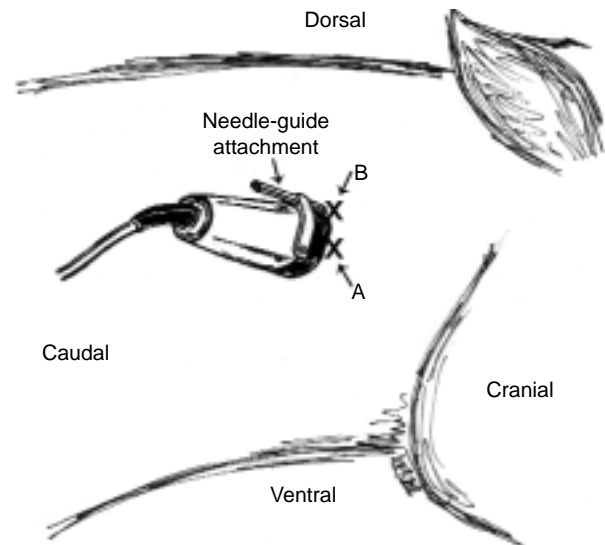


Fig 2: Position of injection sites in relation to transducer, which is shown in relation to the neck during an injection. The needle insertion points are marked; on the right side of the transducer for the free-hand method (A) and dorsal to the transducer with the needle-guide attachment (B).

focus set at 3 cm for all joints, since the depth of the facet joints varied between 2.5 and 3.5 cm. The transducer was held transverse to the line of the vertebrae and turned so the screen displayed ventral to the left. The widest joint space and best access to the joint were located ultrasonographically prior to injection. With the needle-guide attachment, the needle (15.84 cm, 14 gauge) was inserted dorsal to the transducer; without the attachment, the needle (8.0 cm, 14 gauge) was inserted from the right side of the transducer, due to both operators being right-handed (Fig 2), and inserted approximately 2 cm caudally to the transducer with a 60° angle in relation to the skin surface in a cranio-axial direction, depending on the orientation of the facet joint. The longer needle was necessary due to the type of attachment. In both instances, the needle was inserted 4–5 cm until bone was encountered, retracted a fraction, redirected and reinserted a fraction or until the feeling of penetrating the fibrous joint capsule was obtained.

A needle size of 14 gauge was necessary for the solution to pass and a volume of 2 ml was injected into each joint. A solution of 0.25% bromophenol blue dye in 4% agarose was used to avoid diffusion of the deposited material (Schydlofsky *et al.* 1998). The solution, syringes and needles were kept at 80°C until injection to prevent the solution from hardening. Immediately after attempts of joint injection on the second side, the necks were dissected to evaluate accuracy of deposition.

Statistical analysis

For descriptive purposes, the actual location of the injectate found at dissection (the response variable) was scored 1–4, where 1 = intra-articular, 2 = intracapsular, 3 = periarticular <0.5 cm and 4 = periarticular >0.5 cm, and categorised according to the following independent variables: operator, facet, ± use of needle-guide attachment, ± skin and number of neck injected (in chronological order). At a score of 4, the distance from the joint capsule was measured. The score frequency and the 50th, 75th and 95th percentiles were calculated.

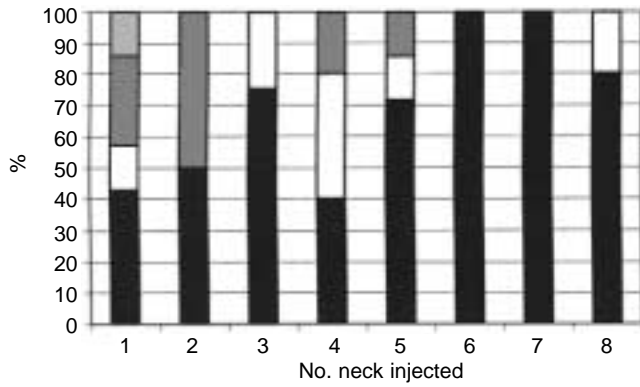


Fig 3: Score (%) according to number of neck injected. The percentage of intra-articular injection increased as the operators gained experience. The distribution between location of deposit is depicted in the diagram. ■ = Periarticular >5 mm (Score 4); ▒ = periarticular <5 mm (Score 3); □ = intracapsular (Score 2); ■ = intra-articular (Score 1).

A 2-sided Chi-square test was applied to examine the association between an independent variable and the likelihood of intra-articular injectate deposition ($P < 0.05$ considered significant). For this purpose, the actual location of the injectate was dichotomised and coded either as failure = 0 (extra-articular, score 2, 3 or 4) or success = 1 (intra-articular, score 1). Fisher's Exact test was used where cell frequencies were below 5. Furthermore, the 8 necks ('number of neck' in chronological order) were regrouped as 'the first 4 necks injected' vs. 'the last 4 necks injected', because the number of observations (injections) per neck was otherwise too sparse and resulted in a higher number of empty cells in cross tabulations. Logistic regression was used to assess the association between the independent variables and response in a multivariable analysis. Only variables that showed a strong or moderate relation in the univariable analysis were considered as candidates for the multivariable analysis ($P < 0.15$). Logistic regression analysis was carried out using the GENMOD procedure in SAS². After examination of the initial model, variables were deleted one by one in a backward and stepwise manual procedure. At each step, the impact of removing one variable on variables left in the model was examined by observing changes in the regression coefficients. If a change of more than 15% was noted, an interaction term (between the variable that changed in regression coefficient and the eliminated variable) was added and examined. If the interaction term was nonsignificant ($P > 0.05$), the original change in regression coefficient was ascribed to multicollinearity. The variable with the highest P value (following Wald's test) was removed first and the procedure was then repeated, until all variables left in the model were associated significantly with the response variable ($P < 0.05$).

TABLE 1: Descriptive statistics for injection scores

Score	Injections	%	s.e.	95% confidence interval
1	43	72	0.06	60–83
2	10	17	0.05	7–26
3	6	10	0.04	2–18
4	1	2	0.02	0–5
Total	60	100	-	-

Scores: 1 = intra-articular, 2 = intracapsular, 3 = periarticular (distance <0.5 cm), 4 = periarticular (distance >0.5 cm).

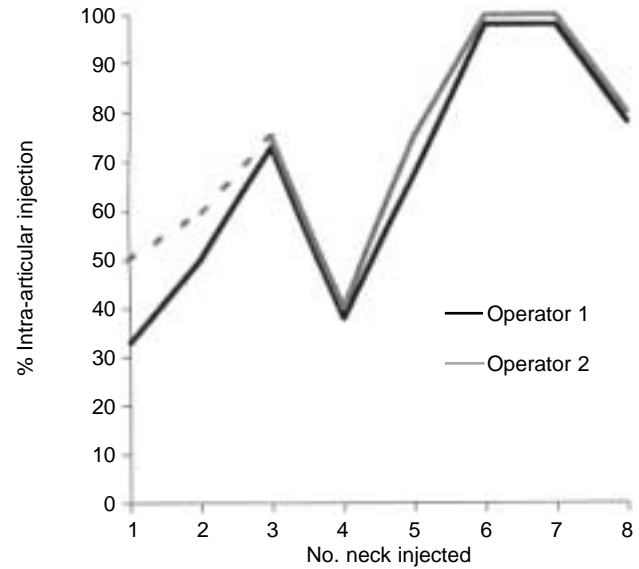


Fig 4: Percentage of intra-articular injection by individual operators according to number of neck injected. The percentage of intra-articular injections increased at a similar rate as the individual operators gained experience. Operator 2 performed no injections on neck No. 2.

Results

The 8 necks contained the facet joints from C2 to C7 and, therefore, 80 potential injection sites. A total of 60 joints could be used for injections; the remaining 20 joints were damaged *post mortem*, making injections impossible. Therefore, the missing values for Operator 2 on Neck 2 were due to extensive damage to the entire side of the neck. The score frequencies are shown in Table 1. Seventy-two percent were found to be intra-articular (95% confidence interval [CI] 60–83%). No deposits were found injected further than 1 mm from the joint capsule, except one in Neck 1, injected 6 mm from the capsule.

The distribution and frequency of intra-articular injections according to number of neck injected are depicted in Figures 3 and 4. A marked increase in the likelihood of an intra-articular injection with increasing experience can be seen. This finding was further confirmed as a highly significant association in the univariable analysis ($P = 0.002$; Table 2). Neither the actual facet joint location ($P = 0.597$) nor operator identity ($P = 0.774$) were significantly associated with correct deposition of injectate. Similarly, neither of the 2 injection techniques (free-hand injection or with needle-guide attachment) was significantly superior to the other ($P = 0.226$). In the univariable analysis, a moderate association ($P = 0.09$) was found between the presence of skin and the likelihood of correct deposition (removal of the skin in 4 horses was necessary to obtain an image). Therefore, only the 2 variables 'neck number injected' and 'skin removed' had $P < 0.15$ and were therefore considered as candidates for multivariable analysis. When these 2 variables were included simultaneously in a multivariable model, only 'neck number injected' was significant ($P = 0.008$), whereas 'skin removed' showed no significant relation to correct deposition of injectate ($P = 0.316$). The regression coefficient of 'neck number injected' changed from -1.907 to -1.777, which is equal to 6.8%, when 'skin removed' was eliminated from the model. Apparently, no strong multicollinearity or interaction existed between the 2 variables.

TABLE 2: Results of univariable analysis (2-sided Chi-square or Fisher's Exact test)

Variable	Level	No. injections extra-articular	No. injection intra-articular	Injections total	P value
Neck No. injected	First four	13	14	27	0.002
	Last four	4	29	43	
Facet joint	Joint 1 (C2–3)	3	11	14	0.597
	Joint 2 (C3–4)	3	11	14	
	Joint 3 (C4–5)	3	10	13	
	Joint 4 (C5–6)	5	8	13	
	Joint 5 (C6–7)	3	3	6	
Operator	Person 1	9	21	30	0.774
	Person 2	8	22	30	
Technique	Manual	12	23	35	0.226
	Needle-guide	5	20	25	
Skin removed	Yes	10	15	25	0.090
	No	7	28	35	

An association between an independent variable and location of injectate were considered significant if $P < 0.05$. Fisher's Exact test was used where cell frequencies were below 5.

Discussion

The aim of this study was to estimate the accuracy of ultrasound-guided intra-articular injections in the cervical facet joint of horses. Seventy-two percent of the injections performed in cadavers were intra-articular. More important, however, is the clear demonstration of an increase in the proportion of intra-articular injections as the operators gained experience resulting in 92% (95% CI: 81–100%) intra-articular injections in Necks 5–8. In a human study of cervical intra-articular facet injections, Barnsley *et al.* (1994) reported a success rate of 90% (38 of 42 joints, 95% CI: 88–100%). Contrary to the present study, their injections were performed by experienced physicians and guided manually with secondary verification by contrast radiography. Contrast verification of needle placement ensures that no intracapsular or periarticular injections are made and would probably further increase the accuracy of intra-articular injections in equine facet joints, but arthrography is a time-demanding and impractical procedure in veterinary practice. Another recognised method of verifying intra-articular position of the needle is aspiration of synovial fluid. Grisel *et al.* (1996) described recovery of synovial fluid from facet joints of living horses but, in the present study, we were unable to retrieve synovial fluid from the joints despite the presence of synovial fluid at subsequent dissection. In our experience, the articular processes of live horses are not always palpable, especially in heavily muscled horses, making localisation of the joints difficult. We would therefore recommend that facet joint injections are performed using an imaging modality.

In addition to the 72% intra-articular injections found in this study, there were 17% intracapsular injections, and those found to be periarticular (12%), were all within 1 mm of the joint capsule, except one injection performed on the first neck. The intracapsular injections were all located in the subsynovial layer between the fibrous portion and synovial intima. A high frequency of intracapsular injections were found in synovial folds, which may be related to the fact that these are found frequently (94%) in equine facet joints (Berg *et al.* 2003). The shift from intra-articular to intracapsular in the fourth neck may

be explained by a time lapse of 2 weeks between Necks 3 and 4, but the difference in percentage of intra-articular injections between Necks 7 and 8 has no obvious explanation. Adequate concentration of the analgesic is likely to reach the nociceptive nerves of the joint when the analgesic is applied intracapsularly or closely periarticularly. A study in human cadavers demonstrated a diffusion of intra-articular injectate through an intact anterior capsule upon the adjacent dorsal root ganglion (Barnsley *et al.* 1993); and Murtagh (2000) stated that analgesic infiltration of a joint with some intracapsular deposition yields acceptable results. The high diffusion rate of local analgesics (Bishop 2001) would cause a low specificity in periarticular injections, but only if pain were present outside the joint structures. Periarticular injection causing a block of the medial branch of the cervical dorsal rami innervating the cervical facet joints is widely used in human medicine. It is described as an easier technique, but the accuracy of diagnosis decreases due to a more unspecific analgesia (Kinard 1996). If intracapsular injections are considered to be of equal diagnostic value to intra-articular injections in this study, diagnostic sensitivity of the ultrasound-guided facet joint injections would reach 89%, and might even increase if the operators gained further experience.

This method can be applied as a diagnostic as well as a therapeutic procedure in the diagnosis of neck stiffness or pain, in assessment of significance of radiographic changes in cervical facet joints as well as in treatment of cervical facet joint pathology of C2 to C7. Unfortunately, we were unable to test the joint of C7–T1 (see *Materials and methods*), but no joint appeared more or less difficult to inject among C2 to C7. However, the results of the present study do not translate directly into injections performed in a live, standing horse. Sedation may be necessary in nervous or needle-shy horses, which may cause the horse to drop its head, making injections more difficult. At the same time, the neck of a sedated horse will be easier to manipulate into an extended and laterally flexed position, which will alter the accessibility of the joint and ease the intra-articular facet joint injection (Grisel *et al.* 1996; Snyder and Spier 2001). If the horse needs to be sedated, the use of longer-lasting analgesia such as bupivacaine or steroids will be necessary for the sedation not to influence diagnostic conclusions based on the injection. Diagnostic injections resulting in a positive effect will then have an additional therapeutic function. Another aspect of intra-articular injection on live horses is that movement can influence the result of an injection. If the horse moves its neck and a needle-guide attachment is used, the simultaneous movement of transducer and needle causes a practical problem. In the present study, no significant association between the likelihood of an intra-articular injection and the use of a needle-guide attachment could be demonstrated. Therefore, the free-hand method, which ensures continuous needle positioning regardless of the movement of the transducer, can be used. Assuming that similar accuracy can be obtained in live horses as in cadavers, we expect 9 out of 10 injections to be either intra-articular or intracapsular and therefore of diagnostic value even for the unexperienced operator. However, practitioners with experience in ultrasonography and ultrasound-guided procedures should have an advantage. The clear effect of experience demonstrated in this study makes it advisable that the clinician practice on cadavers before facet joint injections are performed in live horses.

Acknowledgements

The authors would like to thank Dr Svend Kold for constructive criticism and support and Søren Saxmose Nielsen for advice on the statistical analyses. Erling Nielsen and the staff at Section of Anatomy and Cell Biology and Department of Large Animal Surgery provided invaluable assistance throughout the study. Professor H.E. Jensen of the Department of Pharmacology and Pathobiology and his staff were kind enough to provide the horse material for the study.

Manufacturers' addresses

¹B&K Medical, Gentofte, Denmark.

²SAS Institute Inc., Cary, North Carolina, USA.

References

- Agur, A.M.R. (1999) *Grants Anatomie Atlas und Lernbuch*, 1st edn., Williams & Wilkins, Baltimore. pp 199-254.
- Anon (2000) *2000 SAS/STAT Guide for Personal Computers*, Version 8, Vol. 1-3, SAS Institute Inc., Cary, North Carolina.
- Barnsley, L., Lord, S., Wallis, B. and Bogduk N. (1993) False-positive rates of cervical zygapophysial joint blocks. *Clin. J. Pain* **9**, 124-130.
- Barnsley, L., Lord, S.M., Wallis, B.J. and Bogduk, N. (1994) Lack of effect of intra-articular corticosteroids for chronic pain in the cervical zygapophyseal joints. *New Engl. J. Med.* **14**, 1047-1050.
- Berg, L.C., Nielsen, J.V., Thoenner, M.B. and Thomsen, P.D. (2003) Ultrasonography of the equine cervical region: a descriptive study in eight horses. *Equine vet. J.* **35**, 00-00.
- Bishop, Y. (2001) Drugs acting on the nervous system. In: *The Veterinary Formulary*, 5th edn., Ed: Y. Bishop, Pharmaceutical Press, London. pp 361-414.
- Bogduk, N., Aprill, C. and Derby, R. (1995) Lumbar zygapophyseal joint pain: diagnostic blocks and therapy. In: *Interventional Radiology*, 1st edn., Ed: D.J. Wilson, Edward Arnold, London. pp 75-86.
- Dreyfuss, P.H., Dreyer, S.J. and Herring, S.A. (1995) Contemporary concepts in spine care - lumbar zygapophysial (facet) joint injection: spine. **20**, 2040-2047.
- Grisel, G.R., Grant, B.D. and Rantanen, N.W. (1996) Arthrocentesis of the equine cervical facets. *Proc. Am. Ass. equine Practnrs.* **42**, 197-198.
- Jackson, R.P. (1992) The facet syndrome - myth or reality? *Clin. Orthop. Rel. Res.* **279**, 110-121.
- Kaplan, M., Dreyfuss, P.H., Halbrook, B. and Bogduk, N. (1998) The ability of lumbar medial branch blocks to anesthetise the zygapophysial joint. *Spine* **25**, 1847-1851.
- Kinard, R.E. (1996) Diagnostic spinal injection procedures. *Neurosurg. Clin. N. Am.* **7**, 151-165.
- Külmer, K., Rompe, A., Löwe, A., Herbsthofer, B. and Eysel, P. (1997) Die sonographie der lendenwirbelsäule und des lumbosakralen Überganges. *Wirbelsäule* **135**, 310-314.
- Marks, R.C., Houston, T. and Thulbourne, T. (1992) Facet joint injection and facet nerve block: a randomised comparison in 86 patients with chronic low back pain. *Pain* **49**, 325-328.
- Murtagh, R. (2000) The art and science of nerve root and facet blocks. *Neuroimaging Clin. N. Am.* **10**, 465-477.
- Nelemans, P.J., deBie, R.A., de Vet, H.C. and Sturmans, F. (2001) Injection therapy for subacute and chronic benign low back pain. *Spine* **26**, 501-515.
- Nickel, R., Schummer, A., Seiferle, E., Wilkens, H., Wille, K.H. and Frewein, J. (1986) *The Anatomy of the Domestic Animals - The Locomotor System of the Domestic Mammals*, Vol. 1, 1st edn., Verlag Paul Parey, Berlin.
- Ricardi, G. and Dyson, S.D. (1993) Forelimb lameness associated with radiographic abnormalities of the cervical vertebrae. *Equine vet. J.* **25**, 422-426.
- Schydrowsky, P., Strandberg, C., Trantum-Jensen, J., Bojsen-Møller, F., Jørgensen, U. and Galbo, H. (1998) Post-mortem ultrasonographic assessment of the anterior glenoid labrum. *Euro. J. Ultrasound* **8**, 129-133.
- Slipman, C.W., Lipetz, J.S., Plataras, C.T., Jackson, H.B., Yang, S.T. and Meyer, A.M. (2001) Therapeutic zygapophyseal joint injections for headaches emanating from the C2-3 joint. *Am. J. phys. Med. Rehab.* **80**, 182-188.
- Snyder, J.R. and Spier, S. (2001) Selected intra-articular injections in the horse. In: *Proceedings of the 7th Geneva Congress of Equine Medicine and Surgery*. pp 115-123.
- White, T.D. (2000) ??????. In: *Human Osteology*, 2nd edn., Academic Press, San Diego. pp 139-146.