

■ ENDOMETRITIS IN THE MARE. - THE VALUE OF SWAB AND BIOPSY FOR BACTERIOLOGICAL, CYTOLOGICAL AND HISTOLOGICAL EXAMINATION

Introduction

Collection of samples from the uterine lumen, for diagnosis of potential cause of barrenness in mares, has been common practice since the beginning of the last century¹.

The technique and procedure for collection of samples has since then been modified of several authors^{2,6}. This in mind, the principle however has not changed over time. We still take samples from the uterus and the uterine lumen of barren mares for further diagnosis in the laboratory.

Today there seems to be an agreement among several authors^{2,3}, that not one single laboratory test such as bacteriology, cytology or histology alone will give a satisfactory diagnosis, so that a suitable treatment protocol can be established for each mare. The most reliable diagnosis, possible treatment, and prognosis are established only if tests and methods are used in combination^{2,3,7}.

In this paper different methods for evaluation of samples from the uterus and their diagnostic value regarding bacteriology, cytology and histology will be discussed.

Sampling technique

A double guarded cotton swab (Fig 1) for collection of samples for bacteriology and cytology is widely used all over the world. Different types of biopsy punches (Fig 1) have been developed for tissue sampling deeper in the endometrium, and are used widely in the industry. Tissue samples have mostly been used for histological evaluation of the endometrium^{5,6}.

A new method has recently been published, where the biopsy can be used for bacteriological examination³, if the sample is collected under sterile conditions. This is best achieved, if the endometrial biopsy is collected via a tube speculum through the vagina and the cervical canal (Fig 2). The instruments used has before sampling been autoclaved. The

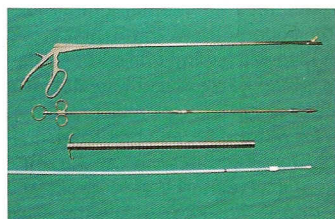


Fig 1. Instruments used for sample collection in the uterus. From above: Biopsy punch of the type Equi-Vet®, divisible biopsy punch, stainless steel tube speculum, disposable Equi-Vet® swab rod.



Fig 2. Endometrial biopsy collected via stainless steel tube speculum. The biopsy is the golden standard, the sensitivity of the


same endometrial biopsy can with this method, be used for bacteriological, cytological and histological examination. The biopsy is first smeared on to an agar for bacteriological examination with a sterile pair of pincers. Then it is smeared on a slide glass for cytological examination, before it is fixed in 5% formaldehyde for potential histological examination.

Bacteriology from a swab and biopsy

Infection with bacteria is a common cause of endometritis. In the laboratory of this author³ the most common isolates are beta-haemolytic Streptococci, E. Coli, Staph Aureus and Pseudomonas Aeruginosa. The species isolated however can vary a lot depending on geography².

The most common method for diagnosing bacteria from the uterus has until recently been swabbing of the endometrial surface. This method however has the disadvantage of giving a lot of false negative results^(2,3).

Comparing results from 212 mares, which both had a swab test, and a culture from an endometrial biopsy as described above, it was demonstrated that the diagnostic value of the biopsy test was superior. In the 212 mares bacteria in monoculture were grown from 36



Jesper Møller Nielsen

DVM
Ansager
Dyrehospital,
Gartnerhaven 5,
6823 Ansager
Denmark
jazz.miller@getznet.dk

References

1. Dimmock WV, Edwards PR. Pathology and bacteriology of the reproductive organs of mares in relation to sterility. In Research Bulletin of the Kentucky Agricultural Experimental Station, No 286, Lexington 1928.
2. Digby NJW, Ricketts SW. Result of concurrent bacteriological and cytological examinations of the endometrium of mares in routine stud farm practice 1978-1981. J. Reprod. Fertil 1982; 32:181-185.



6 Scientific Proceedings Equine Programme

3. Nielsen JM. *Endometritis in the mare: A diagnostic study comparing cultures from swab and biopsy. Theriogenology 2005; 64:510-518.*
4. Knudsen O. A combined cytological and bacteriological endometrial examination in the mare. *Proc Am Assoc Equine Practitioners 1982; 431-433.*
5. Ricketts SW. *Endometrial biopsy as a guide to diagnosis of endometrial pathology in the mare. J Reprod Fertil Suppl 1975; 23:341-345.*
6. Kenney RM, Doig PA. *Equine endometrial biopsy. Current therapy in theriogenology, vol 2. W.B. Saunders; 1986. p. 723-729.*
7. Riddle TW, LeBlanc M, Pierce S, Stromberg AJ. *Relationships between pregnancy rates, uterine cytology, and culture results in a thoroughbred practice in central Kentucky. Proc Am Assoc Equine Practitioners 2005; 198-201.*

swab test can be calculated to 0.44, the specificity 0.98, the positive predictive value 0.95 and the negative predictive value 0.74. In other words: If bacteriology is made from a biopsy, more than twice as many positive cases will be detected, and the number of false negative test will be diminished.

In all cases with growth on both the swab and the biopsy, the same species of bacteria were isolated. This demonstrates, that the bacteria isolated from the swab really are a positive case. It also indicates, that the bacteria found only on the biopsies, is not the result of contamination.

Cytology and histology

Using a quick staining method, detection of polymorph nuclear leucocytes (PMN 's) in a slide prepared from a swab or a biopsy of the endometrium has been demonstrated as a good indicator of endometritis ⁴. Detection of PMN's in the epithelium in a histological preparation however is the best known indicator of endometritis ⁵.

Sending a biopsy to the laboratory for histological examination is time consuming, time that is not available in the middle of the breeding season. Cytological examination can be done at the breeding farm or in the veterinarian's own laboratory, and is therefore a quick and safe alternative.

Results of histology (PMN 's +/-), cytology (PMN 's +/-), and bacteriology from swab and bacteriology from a biopsy were compared in 48 mares. Using histology as the golden standard, the sensitivity of the biopsy method was calculated 0.82, the sensitivity of the swab test was 0.34, and the sensitivity of the cytology test was 0.77. The specificity and positive predictive value of all tests were 1.00. The negative predictive value of biopsy was 0.67, of swab was 0.44, and of cytology was 0.62.

Kenney's classification system and prognosis for pregnancy

Histological examination of an endometrial biopsy is well acknowledged in the industry, as a tool to predict the prognosis for pregnancy in a mare, using the classification system put up by Kenney and Doig in 1986 ⁶. The classification system scores the mare in one of four different groups depending on the histological status of the endometrium. In the first group with normal histological conformation Kenney and Doig predicted a foaling rate of more than 80 %. In group IIa with mild histological changes a foaling rate of 50-80 % were predicted. In group IIb with moderate histological changes a foaling rate of 10-50 % were predicted, and in group III with severe histological changes a foaling rate of less than 10 % were predicted.

In a new study, using the same histological classification system, 74 mares bred at the same breeding farm were biopsied and examined before breeding. Pregnancy (+/-) confirmed by ultrasound at 17 days and foaling (+/-) were recorded and compared to the histological classification as shown in table 1.

Table 1: Results of pregnancy and foaling compared to histological status on 74 mares bred at the same breeding farm

Kenney group foal	number of mares	% pregnant at 17 days	% live
I	11	100	100
IIa	22	82	67
IIb	20	55	35
III	21	28	14

Since the classification system was set up by Kenney and Doig more than twenty years ago methods for care, diagnosis and treatment of problem mares has improved a lot. It could therefore be anticipated, that the prognosis for live foal not longer is the same. The results shown in table one however indicates, that this anticipation is false. The breeding prognosis related to the histological groups set up by Kenney and Doig is still reliable.