



ELSEVIER

Available online at www.sciencedirect.com

SCIENCE @ DIRECT®

Theriogenology

Theriogenology 64 (2005) 510–518

www.journals.elsevierhealth.com/periodicals/the

Endometritis in the mare: A diagnostic study comparing cultures from swab and biopsy

Jesper Møller Nielsen*

*Ansager Dyrehospital (Ansager Large Animal Hospital),
Gartnerhaven 5, DK-6823 Ansager, Denmark*

Abstract

The objective of this study was to compare results from endometrial culture swabs with results from culturing of endometrial biopsies. The culture results were related to cytological findings (polymorphonuclear; PMN-cells) and histological observations (PMN-cells). Biopsy and swab samples were smeared on the surface of a blood agar petri dish, and examined for growth of bacteria. Cytology samples were obtained from endometrial biopsies, stained and examined under microscopy for the presence of PMN-cells. Endometrial biopsies were examined for the presence of PMN-infiltration of the endometrial luminal epithelium and the stratum compactum. Using the presence of PMNs in a tissue specimen as the “best standard” for diagnosing endometritis, the sensitivity of bacterial growth from an endometrial biopsy was 0.82. The sensitivity for cytology was 0.77, and the sensitivity of bacterial growth from an endometrial surface swab was 0.34. The specificity for biopsy cultures, swab cultures, and cytology to diagnose endometritis were 0.92, 1.0, and 1.0 respectively. The positive predictive value for biopsy cultures, swab cultures, and cytology were 0.97, 1.0, and 1.0 respectively. The negative predictive value for biopsy cultures, swab cultures, and cytology were 0.67, 0.44, and 0.62 respectively. In conclusion, bacteriological culture and cytology from an endometrial biopsy provide the practitioner with the most accurate results regarding both sensitivity and positive predictive value.

© 2005 Elsevier Inc. All rights reserved.

Keywords: Endometritis; Endometrial biopsy; Bacteriology; Cytology; Histology

* Tel.: +45 75297066; fax: +45 75296014.

E-mail address: jazz.miller@get2net.dk.

1. Introduction

Bacterial infection in the uterus is recognized as a major cause of reproductive failure in mares [1–12]. In an early study, one-third of all barren mares examined for bacterial growth from an endometrial swab were found to be infected [2]. More recent data indicated that the prevalence of infected barren mares remains high [11]. Bacteriological culture of swabs from the surface of the endometrium has been used in the diagnosis of uterine infection since the beginning of the past century [2,3]. The procedures for sample collection have improved and the use of a guarded swab to obtain samples from the endometrial surface for culture is now common practice [13–15]. All commercially available endometrial swabs are based on a double-guarded, sterile cotton swab. Although the collection of a sample from bacterial culture is non-invasive and simple, the technique may provide false negative results. Later studies reported mares with negative cultures may still have free uterine fluid and or debris on the external genitalia, consistent with endometritis [16,17]. Causes of endometritis, other than bacterial infection, have also been described [18–20].

Histological examination and classification of biopsy material from the endometrium was initially described by several authors [21,22]. Using a biopsy punch, a tissue sample was taken or collected from the endometrium and examined histologically for the presence of inflammation. Depending on the degree of inflammation, fibrosis and glandular degeneration present in the endometrium, mares were classified in one of four categories with regards to expected reproductive performance (I, IIa, IIb, and III) [23,24]. Further development of the classification system, with classification into seven groups related to histological changes and foaling rates, has been proposed by other authors [25]. Correlation between susceptibility to infection and histological changes has been reported [19]. Cytological examination for polymorphonuclear cells (PMN-cells) in a stained smear obtained from the surface of the endometrium is an easy tool for quick diagnosis of uterine inflammation under practical field conditions [12,26–29]. The cytological and histological examination only indicates however, that the mare has inflammation, but does not provide the etiology of the condition.

Examining the accuracy of diagnosis of joint disease, it was demonstrated [30,31] that culture from joint capsule or villi material often resulted in isolation of bacteria, where the result of culture from the synovial fluid from the same joint had been negative. Referring to these observations, we hypothesized that bacteriological culture from endometrial biopsies would be a more sensitive procedure than culture from an endometrial swab.

The objective of this study was to compare culture results from endometrial swabs and endometrial biopsies. The results were related to cytological findings (PMN-cells) and histological observations (PMN-cells).

2. Materials and methods

2.1. Animals

A total of 212 Danish Warmblood and standardbred mares were used in the study, which was conducted from 1996 to 1999. Only mares for which a request was made by owners or

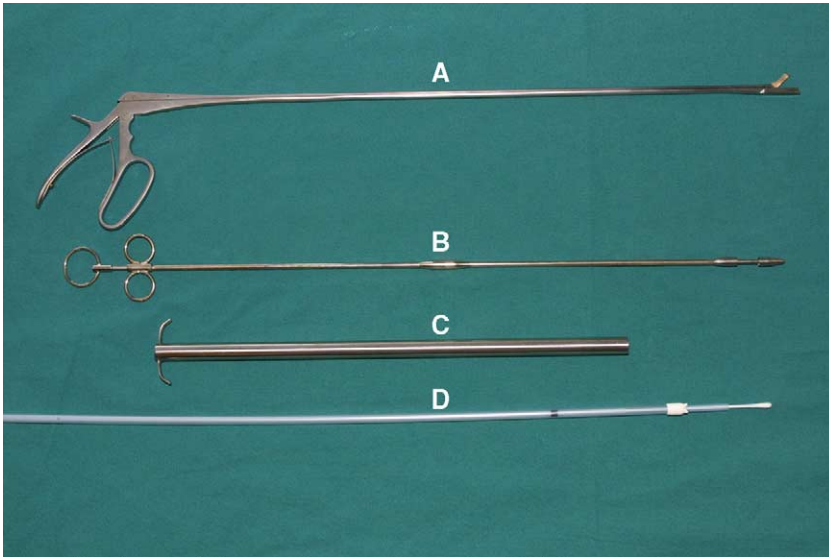


Fig. 1. (Picture 5964) from above: (A) biopsy punch of the type Equi-Vet^R; (B) divisible biopsy punch; (C) stainless steel biopsy speculum; (D) disposable Equi-Vet^R swab rod.

studfarm managers for routine “endometrial culture swabbing” in association with insemination, were included in the study. All mares were in estrus at the time of sampling, and mares were included in the study, whether a history of previous fertility problems was present or not.

2.2. Equipment and procedures for sample collection

Mares were restrained in an examination stock during all procedures. The tail was covered with a disposable examination glove (Equi-Vet^R, Kruuse, Marslev, Denmark), and the vulva and perineal region were rinsed in warm water and then dried with paper. Endometrial biopsies were obtained using sterilized biopsy punch instruments [Equi-Vet^R, Kruuse, Fig. 1A) or Divisible Biopsy Punch (Kruuse; Fig. 1B). A biopsy speculum was designed as a simple stainless steel tube with two small handles in the caudal end (Fig. 1C). Following separation of the vulvar labia, the biopsy speculum was introduced through the vagina and placed in the caudal part of the cervical canal. The tip of biopsy punch was slid through the tube and through the remaining part of the cervical canal into the uterine lumen. The biopsy was taken from the anterior part of the uterine body and the instrument was retracted into the stainless steel tube, which was removed from the vagina. A sterilized pair of pincers was used to smear the biopsy on to a blood agar-plate.

A guarded swab (Equi-Vet^R; Kruuse; Fig. 1D) was used to obtain an endometrial culture, following the procedure described by Brook [29]. The swab was kept in contact with the endometrial surface for at least 30 s. The endometrial biopsy was always obtained before introduction of the guarded swab.

2.3. Microbiology

All samples (biopsies and swabs) were smeared on the surface of a blood agar petri dish (Mueller-Hinton with 5% toxin free calf-blood; Steins Laboratory, Broerup, Denmark).

After 24 h incubation in atmospheric air at 37 °C, growth was identified. Agars with no growth were incubated another 24 h at 37 °C and re-examined [32]. A commercially available, prepacked biochemical reaction system API 20 E^R, API 20 staph^R or API 20 strep^R (Bio Mérieux, Vercieu, France) was used, if further typing of cultures were needed. Only substantial growth in monoculture was recorded as positive growth. If >90% of the grown colonies in an incubated agar was of one species, the result was considered as substantial growth in monoculture. Any other growth in mixed culture was considered to be the result of contamination and recorded as a negative growth result.

2.4. Cytology

The endometrial biopsy was smeared on a microscope glass slide (after being smeared on to the agar). The slide was stained using the Haemacolour^R-system (Merck, Glostrup, Denmark), air-dried and examined by light microscopy (400× magnification) for the presence of PMN-cells. When PMN-cells were present in more than 0.5% of all cells in the sample, it was considered positive for endometritis [33]. A minimum of 200 cells were counted in each sample.

2.5. Histology

Endometrial biopsies for histological examination were fixed in 10% formalin and sent to a referral laboratory for histological preparation and examination. A haematoxylin and eosin stained slide was examined by light microscopy for the presence of PMN-infiltration of the endometrial luminal epithelium and the stratum compactum [33]. Infiltration of one or more PMNs per five fields of high magnification (400×) was considered as evidence of acute endometritis [24].

2.6. Statistics

All comparisons were made by a Chi square test, and significance was set at $P < 0.05$. Sensitivity, specificity, positive predictive value and negative predictive value for different diagnostic tests were calculated. The test that was considered superior in a given comparison was chosen as the best standard. When results of culture from an endometrial biopsy were used as the best standard against culture from an endometrial surface swab, sensitivity was calculated as the proportion of mares with positive growth from an endometrial biopsy and a positive growth from an endometrial swab. Specificity was calculated as the proportion of mares with no growth obtained from an endometrial biopsy and no growth obtained from the endometrial swab. The positive predictive value was calculated as the proportion of mares with positive growth from an endometrial biopsy among the mares with positive growth from an endometrial swab. The negative predictive value was calculated as the proportion of mares with no growth

from an endometrial biopsy among the mares with no growth from an endometrial swab.

When the results of histology were used as the best standard, the presence of PMN-cells in the luminal epithelium and stratum compactum of the endometrium was considered to be an indicator of infection. The sensitivity was calculated as the proportion of mares with PMN-cells in the tissue that was positive in the compared test (e.g. biopsy culture, swab or cytology). The specificity was calculated as the proportion of mares without PMN-cells in the tissue that is negative in the compared test. The positive predictive value was calculated as the proportion of mares with PMN-cells in the tissue among the positive in the compared test. The negative predictive value was calculated as the proportion of mares without PMN-cells in the tissue among the negative in the compared test.

3. Results

Growth of specific bacteria from either swab, biopsy or both was obtained from 39% of all mares (Table 1). The most common bacteria cultured was beta haemolytic *Streptococci* (77%). In 2% of all positive cultures, bacterial growth was observed from the swab and not from the biopsy, and in 55% of positive cultures the swab was negative for bacterial growth while the biopsy cultured positive.

Bacterial growth in monoculture from both the endometrial swab and the endometrial biopsy was observed in 43% of the samples (Table 1). The same bacteria were detected in all pairs of culture in the swab and biopsy groups.

Results obtained from eight (4%) swab cultures and twenty (9%) biopsy cultures were found with growth of more than one type of bacteria. These were considered as contamination and recorded as negative growth. In all these cases of mixed growth, except one, four to six different types of bacterias were seen in equal numbers. In only one case of mixed growth there was growth of only two types of bacteria (approximately 50%

Table 1
Bacteriological growth results from endometrial swab and biopsy cultures from mares

Result		Number (%)	Total (%)
Swab– and biopsy–	No growth	128 (61)	128 (61)
Swab+ and biopsy–	<i>E. coli</i>	2 (1)	2 (1)
Swab– and biopsy+	Beta hem. streptococci	40 (19)	
	<i>Staph. aureus</i>	2 (1)	
	<i>E. coli</i>	2 (1)	
	<i>Pseu. aeruginosa</i>	2 (1)	46 (22)
Swab+ and biopsy+	Beta hem. streptococci	23 (11)	
	<i>E. coli</i>	7 (3)	
	Micrococcus	1 (<1)	
	Fecal streptococci	1 (<1)	
	<i>Pseu. aeruginosa</i>	3 (1)	
	Yeast	1 (<1)	36 (17)
Total		212 (100)	212 (100)

Diagnosis: monoculture growth (+). No growth/low grade mixed growth (–).

Table 2

Results obtained after endometrial culture of mares, presented in a two by two table for calculation of sensitivity

	Biopsy+	Biopsy–	Sum	Sensitivity	Specificity	Positive predictive value	Negative predictive value
Swab+	36 (17%)	2 (1%)	38 (18%)	0.44	0.98	0.95	0.74
Swab–	46 (22%)	128 (60%)	174 (82%)				
Sum	82 (39%)	130 (61%)	212 (100%)				

Swab culture is tested against endometrial biopsy culture as the best standard.

hemolytic *Streptococci* and 50% *E. coli*). The prevalence of mixed growth was not different between the two sample collection methods ($P > 0.1$).

If result of growth (+, –) from the swabs of the 212 mares is tested against growth (+, –) from a biopsy as the “best standard” (Table 2), the sensitivity of the swab test was 0.44. The specificity, positive predictive value and negative predictive value were 0.98, 0.95 and 0.74 respectively.

In a total of 48 of the 212 mares, histological and cytological examination was also performed. The results of these examinations (PMN-cells +, –) are listed in Table 3 in association with numbers of mares with obtained growth (+, –).

Using the presence of PMNs in a tissue specimen from the uterus as the “best standard” for diagnosing endometritis, the sensitivity of bacterial growth from an endometrial biopsy was 0.82. The sensitivity of bacterial growth from an endometrial surface swab was 0.34, and the sensitivity for cytology was 0.77. The specificity for biopsy cultures, swab cultures, and cytology to diagnose endometritis were 0.92, 1.0, and 1.0 respectively.

Table 3

Histological examination of an endometrial biopsy from 48 mares

	Histology+ (PMN+)	Histology– (PMN–)	Sum	Sensitivity	Specificity	Positive predictive value	Negative predictive value
Biopsy+	29 (60%)	1 (2%)	30 (62%)	0.82	0.92	0.97	0.67
Biopsy–	6 (13%)	12 (25%)	18 (38%)				
Sum	35 (73%)	13 (27%)	48 (100%)				
Swab+	12 (25%)	0 (0%)	12 (25%)	0.34	1.00	1.00	0.44
Swab–	23 (48%)	13 (27%)	39 (75%)				
Sum	35 (73%)	13 (27%)	48 (100%)				
Cytology+	27 (56%)	0 (0%)	27 (56%)	0.77	1.00	1.00	0.62
Cytology–	8 (17%)	13 (27%)	21 (44%)				
Sum	35 (73%)	13 (27%)	48 (100%)				

Substantial bacteriological growth (+) or no growth/mixed growth (–) from biopsy smears and endometrial surface swabs was as well as cytological examination from smears (+, –: >0.5% PMN) tested against histological examination (+, –: >one PMN-cell/five high magnification fields (400×). Results from histological examination are used as the best standard.

The positive predictive value for biopsy cultures, swab cultures, and cytology were 0.97, 1.0, and 1.0 respectively. The negative predictive value for biopsy cultures, swab cultures, and cytology were 0.67, 0.44, and 0.62 respectively.

4. Discussion

This study was designed to compare the accuracy of three different laboratory methods for diagnosis of endometritis with results from histological examination. To our knowledge, this is the first time that the sensitivity, specificity, and predictive positive and negative values of bacteriological and cytological examinations have been reported. The detection of PMN-cells in a histological examination of the luminal epithelium and the stratum compactum was considered by the authors to be the most accurate diagnosis of endometritis and uterine infection, and therefore used as a “the best standard”. It has long been recognized that the presence of PMN-cells is the most accurate indication of inflammation, but without positive bacterial culture and identification of a causing agents, it is difficult to propose protocols for treatment of the mare [33]. The sensitivity of bacterial cultures from an endometrial swab was 0.44, compared to samples that were obtained from an endometrial biopsy. “The best standard” is considered to be “the real truth”. However, no test that is chosen as a “the best standard” is 100% accurate, and can consequently always be improved. Results obtained from this study suggest that the sensitivity of microbiological examinations of the equine endometrium can increase by obtaining a sample from a biopsy rather than from an endometrial swab.

Endometrial biopsy is a relatively non-invasive procedure routinely performed by practitioners in the field. Once a biopsy has been obtained, it is easy to smear the specimen on an agar plate for culture. Subsequently there is no need for an endometrial swab.

Since no PMN-cells were detected in stained endometrial smears in any case of samples with mixed growth, all mixed bacterial growth samples were considered to be contamination. The risk of bacterial contamination of samples was similar when either of the two methods for culture was performed. The importance of endometrial cytology in the diagnosis of equine endometritis was initially described [26]. The method was later further developed and described [12,27,34]. These authors used >0.5% PMN-cells of all observed cells under light microscopy as a cut-off to diagnose endometritis in a stained slide from smears obtained from endometrial swabs or biopsies. The correlation between infection and histological evidence of PMN-cells has been described [21–23]. The diagnostic value of detecting PMN-cells is generally considered very high. The detection of PMN-cells in the endometrial epithelium and stratum compactum in a histological preparation/slide has been considered to be the best method of diagnosing uterine inflammation [25]. However the exact sensitivity of this method has not yet been calculated and compared to the sensitivity of other methods in the diagnosis of endometritis, such as bacteriology and cytology.

When histological examinations from endometrial biopsies were used as “the best standard”, the sensitivity of bacteriology obtained from endometrial biopsy (0.82) was superior to both cytological examination (0.77) and bacteriology obtained from an endometrial swab (0.34). This demonstrates that bacteriological diagnosis could be

improved under field conditions, so that both diagnosis of the infection and detection of the agents could be achieved within a short time (few days) with a very high degree of sensitivity. However, a small proportion of samples were considered to be false negative also when this method was used to diagnose endometritis. This could be the result of a lack of sensitivity in laboratory methods for culturing bacteria. For example, culture conditions to promote growth of anaerobic bacteria were not included in this study.

All three tests had a very high positive predictive value (0.97, 1.00 and 1.00). This demonstrates that whichever method is used, a positive sample in any given sample is an accurate indication of endometritis, based on the presence of PMN cells in tissue samples. In contrast, our results suggest that a negative sample is not completely accurate for any of the three methods tested. However, bacteriological examination of an endometrial biopsy and cytological examination were superior to culture swabs also in this regard.

Histological examination of an endometrial biopsy, as shown in this study, is the most reliable diagnostic test for endometritis and uterine infection. The histological examination allows detection of inflammatory response caused by uterine infectious agents and evaluation of chronic degenerative disorders of the endometrium in the same procedure [33]. A practical disadvantage of this method is however, the duration between sampling and laboratory results. This time may not be available for a mare presented in estrus during the breeding season. In comparison, bacteriological results can be cultured overnight.

In conclusion, a combination of bacterial culture from an endometrial biopsy and endometrial cytology were the most accurate and practical method to diagnose equine endometritis.

Acknowledgements

This project was funded by Vetfond, Denmark and the travelscholarship of Intervet Denmark. Thanks for advice and encouragement to Dr. med. vet. Henrik Lehn-Jensen, Royal Veterinary and Agricultural University, Copenhagen; DVM, Ph.D. Preben Christensen, Royal Veterinary and Agricultural University, Copenhagen; and Professor Dr. Mats H. T. Troedsson, University of Florida, Gainesville. Thanks for help with statistics to DVM, Ph.D. Lis Alban, Danske Slagterier, Copenhagen.

References

- [1] Schiebel G. Untersuchungen über bakterienflora im uterus steriler stuten. Inaug dissertation Tierarz. Hochschule Hanover; 1920.
- [2] Dimmock WV, Edwards PR. Bacteria of the genital tract of mares and the semen of stallions and their relation to breeding efficiency. *J Am Vet Med Assoc* 1923;64:288–98.
- [3] Dimmock WV, Edwards PR. Pathology and bacteriology of the reproductive organs of mares in relation to sterility. In *Research Bulletin of the Kentucky Agricultural Experimental Station*, No. 286, Lexington; 1928.
- [4] Merkt H. Überwachung der fruchtbarkeit in der vollblutsucht. *Dtsch Tierarzl Wschr* 1957;64:152–4.
- [5] Bain AM. The role of infection in infertility in the thoroughbred mare. *Vet Rec* 1966;78:168–73.
- [6] Digby NJW, Ricketts SW. Results of concurrent bacteriological and cytological examinations of the endometrium of mares in routine stud farm practice 1978–81. *J Reprod Fertil* 1982;32:181–5.

- [7] Merkt H, Wöckener A, Heilbrinker T, Zemke M. Mikrobielle untersuchung in der stuten gynaekologie. *PraktTierarz* 1987;68:5–12.
- [8] Ricketts SW, McKintosh ME. Role of anaerobic bacteria in equine endometritis. *J Reprod Fertil Suppl* 1987;35:343–51.
- [9] Bocklisch HV, Kunter E, Ludwig E, Weidehaas H. Bakteriologische untersuchung von cervixutepfer- und uterusproben im rahmen des pferdegesundheitsdienstes unter besonderer berücksichtigung von beta-haemolysierenden streptokokken. *Monat Vetmed* 1988;43:609–12.
- [10] Hinrichs K, Cummings MR, Sertich PL, Kenney RM. Bacteria recovered from reproductive tracts of normal mares. *Proc Am Assoc Equine Practitioners* 1989;35:11–6.
- [11] Ricketts SW, Young A, Medici EB. Uterine and clitoral cultures. In: McKinnon, Voss, editors. *Equine reproduction*. Lea & Febiger; 1993. p. 234–45.
- [12] Reiswig JD, Threllfall WR, Rosol TJ. A comparison of endometrial biopsy, culture and cytology during oestrus and dioestrus in the horse. *Equine Vet J* 1993;25:240–1.
- [13] Blanchard T, Garcia MC, Hurtgen JP, Kenney RM. Comparison of two techniques for obtaining endometrial bacteriologic cultures in the mare. *Theriogenology* 1981;1:85–93.
- [14] Blanchard TL, Cummings MR, Garcia MC, Hurtgen JP. Comparison between two techniques for endometrial swab culture and between biopsy and culture in mares. *Theriogenology* 1981;5:541–52.
- [15] Brook D. Uterine cultures in mares. *Mod Vet Practice* 1984;65:A3–8.
- [16] Pycock JF, Newcombe JR. The relationship between intraluminal uterine fluid, endometritis and pregnancy rate in the mare. *Equine Pract* 1996;18:19–22.
- [17] Pycock JF, Paccamonti D, Jonker H, Newcombe J, van der Weijden G, Taverne M. Can mares be classified as resistant or susceptible to recurrent endometritis. *Pferdeheilkunde* 1997;5:431–6.
- [18] Kotilainen T, Huhtinen M, Katila T. Sperm induced leucocytosis in the equine uterus. *Theriogenology* 1994;41:629–36.
- [19] Troedsson MHT, Marcos JDM, Irwin KML. Correlations between histologic endometrial lesions in mares and clinical response to intrauterine exposure with *Streptococcus zooepidemicus*. *Am J Vet Res* 1993;4:570–2.
- [20] Troedsson MHT, Steiger BN, Ibrahim NM, Foster DN, Garbo BG. Mechanism of sperm-induced endometritis in the mare. *Biol Reprod* 1995;52:307.
- [21] Kenney RM. Clinical aspects of endometrial biopsy in fertility evaluation of the mare. *Proc Am Assoc Equine Practitioners* 1977;105–22.
- [22] Ricketts SW. Endometrial biopsy as a guide to diagnosis of endometrial pathology in the mare. *J Reprod Fertil Suppl* 1975;23:41–345.
- [23] Kenney RM, Doig PA. *Equine endometrial biopsy*. Current therapy in theriogenology, vol. 2. W.B. Saunders; 1986. p. 723–9.
- [24] Ricketts SW, Alonso S. Assessment of the breeding prognosis of mares using paired endometrial biopsy techniques. *Equine Vet J* 1991;23:185–8.
- [25] Schoon HA, Schoon D, Klug E. Die endometriumbiopsie bei der stute in klinisch-gynäkologischen kontext. *Pferdeheilkunde* 1997;5:453–64.
- [26] Knudsen O. Endometrial cytology as a diagnostic aid in mares. *Cornell Vet* 1964;54:415–22.
- [27] Digby NJW. Studies of endometrial cytology in mares. *Equine Vet J* 1978;10:167–70.
- [28] Knudsen O. A combined cytologic and bacteriologic endometrial examination in the mare. *Proc Am Assoc Equine Practitioners* 1982;431–3.
- [29] Brook D. Exfoliative endometrial cytology in the mare. Master thesis. Stellenbosch, South Africa; 1983.
- [30] De Gara PF. Studies of bactericidal properties of synovial fluid. *J Clin Invest* 1943;22:131.
- [31] McIlwraith CW. Infectious arthritis. In: Adam's Lameness in horses 4th ed., Lea & Febiger; 1994 p. 423–32.
- [32] Macintosh ME. Bacteriological techniques in the diagnosis of equine genital infections. *Vet Rec* 1981;108:52–5.
- [33] Ricketts SW. The treatment of equine endometritis in studfarm practice. *Pferdeheilkunde* 1999;6:588–93.
- [34] Williamson P, Munyua S, Martin R, Penhale WJ. Dynamics of the acute uterine response to infection, endotoxin infusion and physical manipulation of the reproductive tract in the mare. *J Reprod Fertil* 1987;35:317–25.